



Riporto con molto piacere una recente review pubblicata su questa importante rivista internazionale che pone ulteriore chiarezza sulle linee guida del nodulo tiroideo con particolare rilevanza alla diagnosi e alla terapia.

Ho avuto il piacere di essere citato nelle references del lavoro in quanto autore e coautore di articoli che ponevano l'importanza dell'uso della alcolizzazione per cutanea nel nodulo tiroideo sia scintigraficamente caldo che in quello freddo e cistico.

Tengo a sottolineare che nella parte dedicata alla terapia del nodulo tiroideo l'uso della levo-tiroxina sodica a scopo soppressivo il TSH nel nodulo tiroideo benigno scintigraficamente non funzionante viene da me consigliata e consente di controllare la crescita del nodulo tiroideo senza determinare problemi sulla massa ossea.

The Thyroid Nodule

Laszlo Hegedüs, M.D.

The Clinical Problem

In the United States, 4 to 7 percent of the adult population have a palpable thyroid nodule.¹ However, only 1 of 20 clinically identified nodules is malignant. This corresponds to approximately 2 to 4 per 100,000 people per year, constituting only 1 percent of all cancers and 0.5 percent of all cancer deaths.² Nodules are more common in women and increase in frequency with age and with decreasing iodine intake. The prevalence is much greater with the inclusion of nodules that are detected by ultrasonography or at autopsy. By the latter assessment, approximately 50 percent of 60-year-old persons have thyroid nodules.³

The clinical spectrum ranges from the incidental, asymptomatic, small, solitary nodule, in which the exclusion of cancer is the major concern, to the large, partly intrathoracic nodule that causes pressure symptoms, for which treatment is warranted regardless of cause.³ The most common diagnoses and their approximate distributions are colloid nodules, cysts, and thyroiditis (in 80 percent of cases); benign follicular neoplasms (in 10 to 15 percent); and thyroid carcinoma (in 5 percent).

The management of a solitary thyroid nodule remains controversial.^{3,4,5} This review will focus on the management of a solitary thyroid nodule that is detected on physical examination, regardless of

the finding of additional nodules by radionuclide scanning or ultrasonography, since such a finding does not alter the risk of cancer.³

Strategies and Evidence

History and Physical Examination

The history and physical examination remain the diagnostic cornerstones in evaluating the patient with a thyroid nodule and may be suggestive of thyroid carcinoma (Table 1). However, a minority of patients with malignant nodules have suggestive findings, which often also occur in patients with benign thyroid disorders. There is also substantial variation among practitioners in evaluating nodules,^{2,6} a finding that may explain why an increasing number of thyroid specialists use imaging as part of the evaluation.^{4,5}

Table 1. Clinical Findings Suggesting the Diagnosis of Thyroid Carcinoma in a Euthyroid Patient with a Solitary Nodule, According to the Degree of Suspicion

Table 1. Clinical Findings Suggesting the Diagnosis of Thyroid Carcinoma in a Euthyroid Patient with a Solitary Nodule, According to the Degree of Suspicion.
High suspicion Family history of medullary thyroid carcinoma or multiple endocrine neoplasia Rapid tumor growth, especially during levothyroxine therapy A nodule that is very firm or hard Fixation of the nodule to adjacent structures Paralysis of vocal cords Regional lymphadenopathy Distant metastases
Moderate suspicion Age of either <20 years or >70 years Male sex History of head and neck irradiation A nodule >4 cm in diameter or partially cystic Symptoms of compression, including dysphagia, dysphonia, hoarseness, dyspnea, and cough

The risk of thyroid cancer seems nearly as high in incidental nodules (<10 mm), the majority of which escape detection by palpation, as in larger nodules.⁷ However, the vast majority of these microcarcinomas do not grow during long-term follow-up and do not cause clinically significant thyroid cancer.⁸ The fact that ultrasonography detects nodules (a third of which are more than 20 mm in diameter) in up to 50 percent of patients with a normal neck examination underscores the low specificity and sensitivity of clinical examination.² When two or more risk factors that indicate a high clinical suspicion are present, the likelihood of cancer approaches 100 percent.¹⁰ In such cases,

biopsy is still useful to guide the type of surgery^{1,2} (Figure 1). **Figure 1.** Algorithm for the Cost-Effective Evaluation and Treatment of a Clinically Detectable Solitary Thyroid Nodule.

In the case of a strong clinical suspicion of cancer, surgery is recommended, regardless of the results of fine-needle aspiration biopsy (FNAB). In the case of a suppressed level of serum thyrotropin, thyroid scintigraphy should be performed, since a functioning nodule almost invariably rules out cancer. In the case of a nondiagnostic FNAB, a repeated biopsy yields a satisfactory aspirate in 50 percent of cases. If ultrasonography reveals additional nodules that are more than 10 mm in diameter, FNAB could be performed on one other nodule, in addition to the one that is clinically detectable. The therapeutic options shown cover both solid and cystic nodules. In the case of a recurrent cyst, the possibilities of treatment are repeated FNAB, surgery, and ethanol injection. I do not recommend levothyroxine therapy for the thyroid nodule.

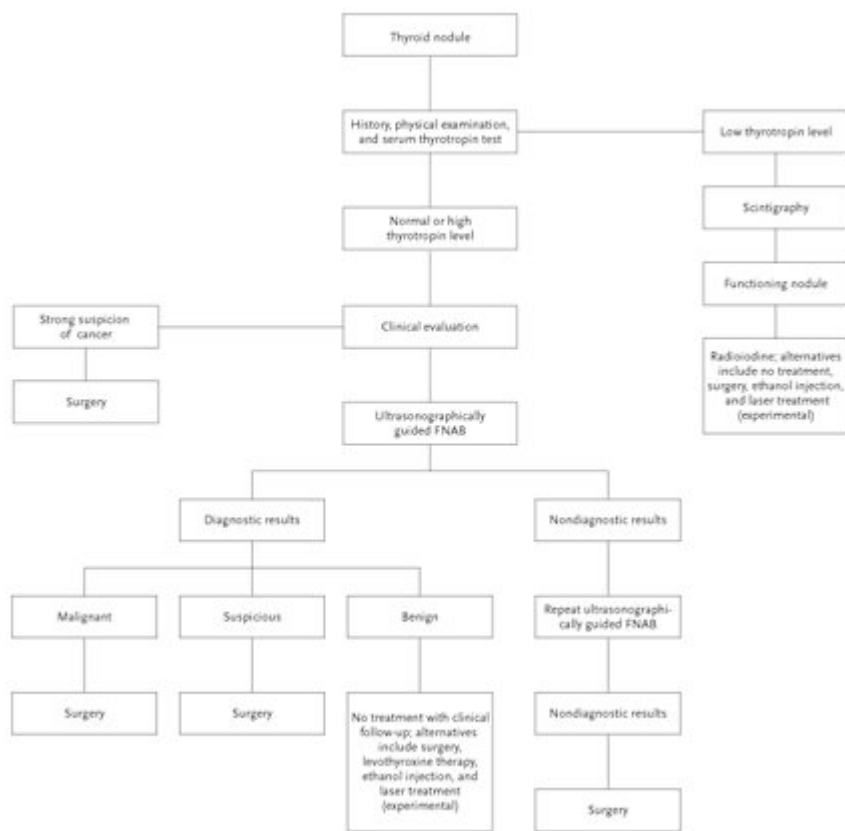


Figure 1. Algorithm for the Cost-Effective Evaluation and Treatment of a Clinically Detectable Solitary Thyroid Nodule.

In the case of a strong clinical suspicion of cancer, surgery is recommended, regardless of the results of fine-needle aspiration biopsy (FNAB). In the case of a suppressed level of serum thyrotropin, thyroid scintigraphy should be performed, since a functioning nodule almost invariably rules out cancer. In the case of a nondiagnostic FNAB, a repeated biopsy yields a satisfactory aspirate in 50 percent of cases. If ultrasonography reveals additional nodules that are more than 10 mm in diameter, FNAB could be performed on one other nodule, in addition to the one that is clinically detectable. The therapeutic options shown cover both solid and cystic nodules. In the case of a recurrent cyst, the possibilities of treatment are repeated FNAB, surgery, and ethanol injection. I do not recommend levothyroxine therapy for the thyroid nodule.

Laboratory Investigations

Because clinical examination is not sensitive for identifying thyroid dysfunction,⁶ laboratory evaluation of thyroid function is routinely warranted. The only biochemical test routinely needed is measurement of the serum thyrotropin level. If this level is subnormal, levels of free thyroxine or free triiodothyronine should be measured to document the presence and degree of hyperthyroidism. Approximately 10 percent of patients with a solitary nodule have a suppressed level of serum thyrotropin, which suggests a benign hyperfunctioning nodule.² If the serum thyrotropin concentration is elevated, a serum antithyroperoxidase antibody level should be obtained to confirm Hashimoto's thyroiditis. However, the finding of an elevated level does not obviate the need for a fine-needle aspiration biopsy, since the practitioner must rule out a coexisting cancer, including lymphoma, which accounts for only 5 percent of thyroid cancers but is associated with Hashimoto's thyroiditis.¹¹ Nearly all patients with thyroid cancer are euthyroid.¹

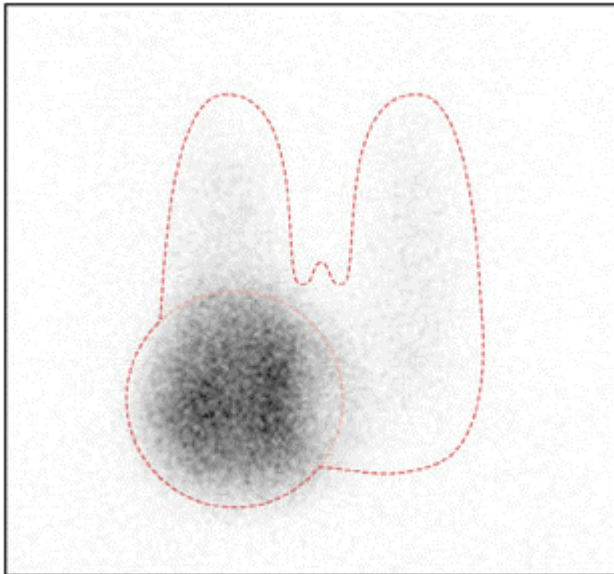
If a patient has a family history of medullary thyroid cancer or multiple endocrine neoplasia type 2, a basal serum calcitonin level should be obtained; an elevated level suggests medullary thyroid cancer. Before surgery is performed, investigation for primary hyperparathyroidism and pheochromocytoma should be carried out. Serum calcitonin is not routinely measured in patients who have no suggestive family history, since medullary carcinoma is present in only about 1 of 250 patients with a thyroid nodule.¹²

Imaging of the Thyroid Nodule

Radionuclide Scanning

Radionuclide scanning, which is performed much more commonly in Europe than in the United States,^{3,4,5} may be used to identify whether a nodule is functioning ([Figure 2](#)). A functioning nodule, with or without suppression of extranodular uptake, is nearly always benign, whereas a nonfunctioning nodule, constituting approximately 90 percent of nodules, has a 5 percent risk of being malignant. Thus, in the patient with a suppressed level of serum thyrotropin, radionuclide confirmation of a functioning nodule may obviate the need for biopsy. A scan can also indicate whether a clinically solitary nodule is a dominant nodule in an otherwise multinodular gland and can reveal substernal extension of the thyroid. A scan can be performed with iodine-123, iodine-131, or technetium-99m-labeled pertechnetate. Iodine isotopes, which are both trapped and bound organically in the thyroid, are preferred, since 3 to 8 percent of nodules that appear functioning on pertechnetate scanning may appear nonfunctioning on radioiodine scanning, and a few of those nodules may be thyroid cancers.¹³ A scan cannot be used to measure the size of a nodule accurately.

Figure 2. Scintigram of a Solitary Functioning Nodule in the Right Thyroid Lobe.

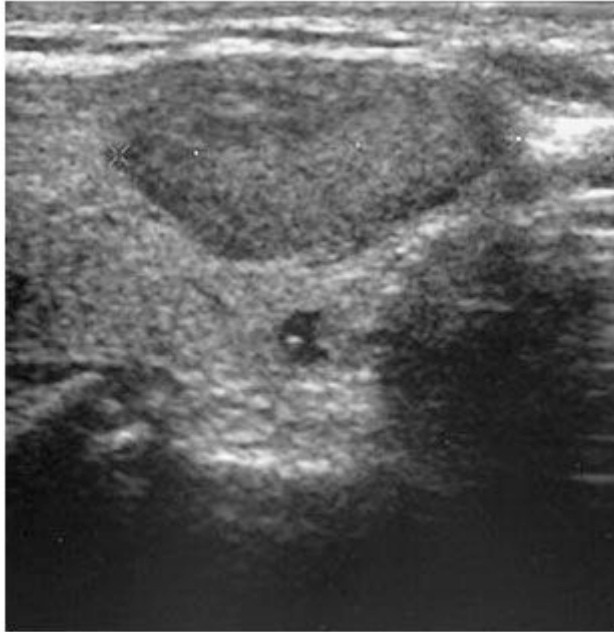

Scintigraphy that was performed with the use of technetium-99m–labeled pertechnetate shows suppression of extranodular uptake in thyroid tissue.

Ultrasonography

Ultrasonography can accurately detect nonpalpable nodules, estimate the size of the nodule and the volume of the goiter, and differentiate simple cysts, which have a low risk of being malignant, from solid nodules or from mixed cystic and solid nodules, which have a 5 percent risk of being malignant ([Figure 3](#)). Ultrasonography also provides guidance for diagnostic procedures (e.g., fine-needle aspiration biopsy) as well as therapeutic procedures (e.g., cyst aspiration, ethanol injection, or laser therapy) and facilitates the monitoring of the effects of treatment.⁹ In one study, among patients who had been referred for evaluation of a palpable thyroid abnormality, ultrasonography altered the clinical management in two thirds of cases,¹⁴ mainly by identifying nodules that were smaller than 1 cm (which were not considered to require further evaluation) in 20 percent of the patients and by discovering additional nodules (which required biopsy) in 24 percent of the patients. Characteristics revealed by ultrasonography — such as hypoechogenicity, microcalcifications, irregular margins, increased nodular flow visualized by Doppler, and, especially, the evidence of invasion or regional lymphadenopathy — are associated with an increased risk of cancer; however, sonographic findings cannot reliably distinguish between benign and cancerous lesions.⁹

Figure 3. Cross-Sectional Ultrasonogram Showing a Solid, Hypoechoic Nodule (Dark Gray) in the Right Thyroid Lobe.



Other Methods

Computed tomography (CT) and magnetic resonance imaging also cannot reliably differentiate between malignant and benign nodules. These tests are rarely indicated in the evaluation of a nodule. An exception is in the diagnosis and evaluation of substernal goiters, since these imaging techniques can assess the extent of the goiter more precisely than can other techniques and can evaluate tracheal compression.^{3,15} Evaluation of glucose metabolism by positron-emission tomography using fludeoxyglucose (fluorodeoxyglucose) F 18 may help in distinguishing benign from malignant nodules, but its use is limited by cost and accessibility¹⁶ and it cannot replace biopsy.

Fine-Needle Aspiration Biopsy

Independent of morphology, fine-needle aspiration provides the most direct and specific information about a thyroid nodule. It is performed on an outpatient basis,^{1,4,5} is relatively inexpensive, and is easy to learn. Complications are rare and primarily involve local discomfort. The use of anticoagulants or salicylates does not preclude biopsy. In centers with experience in fine-needle aspiration, the use of this technique has been estimated to reduce the number of

thyroidectomies by approximately 50 percent, to roughly double the surgical confirmation of carcinoma, and to reduce the overall cost of medical care by 25 percent,¹⁷ as compared with surgery performed on the basis of clinical findings alone.

Fine-needle aspiration has diagnostically useful results in about 80 percent of cases,¹⁸ typically with two to four passes of the needle. The number of cases in which sufficient samples are obtained increases if aspiration is guided by ultrasonography, especially in nodules that are partly cystic, and repeated biopsy reduces by half the rate of insufficient samples (to about 10 percent).^{19,20} The diagnostic accuracy of fine-needle aspiration depends on the way in which suspicious lesions are handled. Viewing them as "positive" increases sensitivity (rate of false negative results, 1 percent), but decreases specificity.²¹ If fine-needle aspiration reveals a follicular neoplasm (which occurs in approximately 15 percent of nodules, of which only 20 percent turn out to be malignant), radionuclide scanning should be performed.^{1,2,3} If such scanning shows a functioning nodule with or without complete suppression of the rest of the thyroid, surgery can be avoided, since the risk of cancer is negligible.¹⁷ In a cystic lesion or one that is a mixture of cystic and solid components, fine-needle aspiration of a possible solid component should be performed, since the risk of cancer is the same as that for a solid nonfunctioning nodule.^{2,20,21} With the exception of calcitonin immunostaining for medullary carcinoma, there are no reliable immunohistologic or molecular tests for distinguishing between benign and malignant nodules.³

Treatment of the Solitary Thyroid Nodule

The natural history of solitary thyroid nodules is poorly understood, mainly because nodules that are suspicious for cancer, cause pressure, or prompt reports of cosmetic problems are rarely left untreated. With this reservation, it seems that the majority of benign nonfunctioning nodules grow, particularly those that are solid.^{22,23,24} In one study, 89 percent of nodules that were followed for five years increased by 15 percent or more in volume.²⁴ The annual rate of evolution of a solitary functioning nodule into a hyperfunctioning nodule is as high as 6 percent; the risk is positively related to the size of the nodule and negatively related to the serum thyrotropin level.^{25,26} There is controversy as to whether a solitary nodule should be treated and, if so, how.^{4,5} [Table 2](#) summarizes the advantages and disadvantages of potential treatment options. [Figure 1](#) shows a management algorithm.

Table 2. Treatment of the Single Nonmalignant Thyroid Nodule.

Table 2. Treatment of the Single Nonmalignant Thyroid Nodule.		
Treatment Type	Advantages	Disadvantages
Surgery	Nodule ablation, complete relief of symptoms, definite histologic diagnosis	Need for hospitalization, high cost, risks associated with surgery, vocal-cord paralysis (approximately 1% of patients), hypoparathyroidism (<1%), hypothyroidism (approximately 1% [*])
Levothyroxine	No need for hospitalization, low cost, may slow nodule growth, may prevent new nodule formation	Low efficacy, need for lifelong treatment, regrowth of nodule after cessation of treatment, cardiac tachyarrhythmias, reduced bone density, not feasible when thyrotropin level is suppressed
Radioiodine [†]	No need for hospitalization, low cost, few subjective side effects, nodule reduced by 40% in 1 yr	Use of contraceptives needed in fertile women, only gradual reduction of the nodule, hypothyroidism within 5 yr (10% of patients), risk of radiation thyroiditis and thyrotoxicosis
Ethanol injection	No need for hospitalization, relatively low cost, no hypothyroidism, nodule reduced by 45% in 6 mo	Limited experience with treatment, decreasing efficacy with increasing nodule size, success dependent on operator's skill, painful (reducing compliance), risk of thyrotoxicosis and vocal-cord paralysis (approximately 1–2%), seepage of ethanol, [‡] interpretation of cytologic and histologic findings impeded in treated nodules
Laser therapy [§]		

* This risk applies only to the case of hemithyroidectomy.

[†] This treatment is used only for the functioning thyroid nodule.

[‡] Side effects due to the seepage of ethanol outside the nodule, which are rare (occurring in about 1 percent of patients), comprise nerve damage, perinodular or periglandular fibrosis jeopardizing subsequent surgery, thrombosis of the jugular vein, and neck hematomas.

[§] Laser therapy is still experimental, and experience with it is limited. The advantages are the same as those of ethanol injection, but side effects are probably more limited because the higher degree of control with laser therapy limits the risk of extranodular damage.

Levothyroxine

Treatment with levothyroxine at a dose sufficient to keep the serum thyrotropin at a level below 0.3 mU per liter has been suggested as a way to prevent growth of an apparently benign nodule. However, this approach has clear limitations. A recent meta-analysis showed no significant difference in the size of nodules after 6 to 12 months of suppressive therapy with levothyroxine, as compared with no treatment, although the size of the nodules decreased by more than 50 percent in a larger proportion of levothyroxine-treated patients than in patients who had no treatment.²⁷ The likelihood of such shrinkage is greater when serum thyrotropin is suppressed to a level below 0.1 mU per liter than it is when the level is below 0.3 mU.^{27,28,29} In a five-year, randomized trial, suppression to below 0.1 mU per liter significantly reduced the frequency with which new nodules developed (i.e., 8 percent of patients who were treated with levothyroxine as compared with 29

percent of untreated patients).²⁹ However, therapy with levothyroxine to reduce thyrotropin levels below 0.1 mU per liter is associated with an increased risk of atrial fibrillation, other cardiac abnormalities,^{30,31} and reduced bone density.³² Regrowth of nodules occurs after cessation of therapy. Levothyroxine has no effect on the recurrence of thyroid cysts after aspiration.³³

Surgery

The main indications for surgery are clinical or cytologic features suggestive of cancer or symptoms due to the nodule ([Table 1](#)).^{4,5} If preoperative cytology suggests a benign lesion, hemithyroidectomy is generally preferred.^{4,5,18} Postoperative administration of levothyroxine is indicated only in cases of hypothyroidism.³⁴ When surgery is performed by a specialist, the incidence of complications is low (i.e., postoperative hypoparathyroidism in 1 percent of cases and injuries to the recurrent laryngeal nerve in about 1 percent), but the complication rate is higher for less experienced surgeons and those without special training.³⁵

Radioiodine

Radioiodine is an option for treatment of a functioning nodule, with or without biochemical hyperthyroidism. It is contraindicated in pregnant and breast-feeding women. Normalization of the results of thyroid radionuclide scanning and the serum thyrotropin level (often referred to as a "cure") is achieved in 75 percent of patients, and thyroid volume is reduced an average of 40 percent, after a single dose of iodine-131 aiming at a level of 100 Gy, independent of pretreatment thyroid function.^{36,37} The main side effect is hypothyroidism, which occurs in approximately 10 percent of patients within five years after treatment and increases in frequency over time. This risk is unrelated to dose but is greater in patients with thyroid peroxidase antibodies and with iodine uptake in extranodular thyroid tissue.^{36,37} Most nodules do not disappear after radioiodine therapy but may become harder on palpation and may reveal unusual cytologic features as a result of irradiation. Thyroid function should be checked regularly during the first year and yearly thereafter in order to detect hypothyroidism. Nodules are unlikely to grow after radioiodine therapy, but if growth occurs, a biopsy may be warranted.

Percutaneous Ethanol Injection

A number of studies have suggested a benefit of ultrasonographically guided ethanol injection in the treatment of benign functioning and nonfunctioning solid thyroid nodules as well as cystic nodules.^{38,39,40} The mechanism of effect involves coagulative necrosis and small-vessel thrombosis. The procedure requires prior documentation of benign cytology, skill, and experience^{3,9}; drawbacks include local pain and a potential risk of serious side effects ([Table 2](#)). There are few data from controlled trials to support this approach.

Available data suggest that multiple injections of ethanol (a median of four) can achieve a complete cure (i.e., a normalization of results of radionuclide scanning and serum thyrotropin measures) in two thirds of patients with hyperfunctioning nodules and three quarters of patients with functioning nodules without hyperthyroidism.^{38,39} In solid nonfunctioning nodules that are solitary and cytologically benign, a single ethanol injection has been shown to reduce the volume of nodules by approximately 50 percent.^{3,23} Additional ethanol injections have only a limited effect.^{41,42} Recently, data from a preliminary study suggested that the use of laser photocoagulation may be as effective as ethanol injection, with fewer adverse effects.⁴³ However, controlled trials are needed.

In thyroid cysts, the recurrence rate after aspiration is high. Tetracycline, a sclerosing agent, had no effect in a randomized study.⁴⁴ Uncontrolled studies have suggested that ethanol injection may

prevent the recurrence of cysts.^{39,40} A recent randomized, double-blind study⁴⁵ involving a six-month follow-up period reported that 21 of 33 patients (64 percent) who were treated with ethanol were cured after one session, as compared with 6 of 33 patients (18 percent) who were treated with saline.

Areas of Uncertainty

There are no data from studies comparing the outcome and cost-effectiveness of various strategies of evaluating a nodule (e.g., using radionuclide imaging and ultrasonographic guidance for fine-needle aspiration). There are also insufficient data comparing the outcome (including quality of life) of various management approaches in the absence of cancer.

Guidelines from Professional Societies

Clinical-practice guidelines were published in 1996 by the American Thyroid Association¹ (www.thyroid.org/professionals/publications/guidelines.html) and the American Association of Clinical Endocrinologists⁴⁶ (www.aace.com/clin/guidelines/thyroid_nodules.pdf). The recommendations of both organizations correspond with those provided here. Radionuclide scanning is not routinely recommended, but it is advocated in the case of a suppressed level of serum thyrotropin or the finding of follicular neoplasia with the use of fine-needle aspiration. Thyroid ultrasonography is recommended to guide fine-needle aspiration, especially in nodules that are small and incidental or are partly cystic or from which primary fine-needle aspiration has yielded insufficient material. Fine-needle biopsy of all possibly malignant nodules (which are not defined in the guidelines) is advocated. If the cytology is benign, repeated biopsy is seldom indicated.

In the case of a benign nodule, periodic lifelong follow-up every 6 to 24 months (including measurement of serum thyrotropin levels, neck palpation, and fine-needle aspiration in case of growth or other suspicious signs) is recommended. For a functioning benign nodule, iodine-131 is considered the treatment of choice, with surgery as an alternative, especially if the nodule is very large or partly cystic or if the patient is young; treatment is more strongly recommended if the serum thyrotropin level is decreased or overt hyperthyroidism is present, because of adverse effects on bone and the cardiovascular system. For a nonfunctional benign nodule, there is no clear recommendation on the use of levothyroxine, although this therapy is considered contraindicated when the serum thyrotropin level is suppressed, in patients more than 60 years old, and in postmenopausal women. If levothyroxine therapy is used, regular reassessment (the interval is not defined in the guidelines) is recommended, with monitoring of serum thyrotropin levels, which should be subnormal but measurable. The guidelines do not address ethanol injection and laser therapy.

Conclusions and Recommendations

For the patient who presents with a nodule, as in the case described in the vignette, the main concern is to exclude the possibility of thyroid cancer, even though the vast majority of nodules are benign ([Figure 1](#)). The initial evaluation should include measurement of the serum thyrotropin level and a fine-needle aspiration, preferably guided by ultrasonography. If the patient has a family history of medullary thyroid carcinoma or multiple endocrine neoplasia type 2, the serum calcitonin level should also be checked. If the thyrotropin level is suppressed, radionuclide scanning should be performed. In patients less than 20 years old, and in the case of a high clinical suspicion for cancer (e.g., follicular neoplasia as diagnosed by fine-needle aspiration and a nonfunctioning nodule

revealed on scanning), the patient should be offered hemithyroidectomy regardless of the results of fine-needle aspiration.

In the case of a functioning benign nodule, iodine-131 is generally the therapy of choice, independent of concomitant hyperthyroidism. For nonfunctioning cystic nodules, aspiration and ethanol injection therapy may be considered, and ethanol injection or laser therapy if the nodules are solid, but data to support the use of these therapies are limited. My usual approach after documenting benign cytology is to follow the patient yearly with neck palpation and measurement of the serum thyrotropin level, with repeated ultrasonography and fine-needle aspiration if there is evidence of growth of the nodule. I do not recommend levothyroxine therapy to shrink or prevent growth of benign nodules because of the drug's low efficacy and potential side effects.

References

1. Singer PA, Cooper DS, Daniels GH, et al. Treatment guidelines for patients with thyroid nodules and well-differentiated thyroid cancer. *Arch Intern Med* 1996;156:2165-2172. [\[Abstract\]](#)
2. Wong CKM, Wheeler MH. Thyroid nodules: rational management. *World J Surg* 2000;24:934-941. [\[CrossRef\]](#)[\[ISI\]](#)[\[Medline\]](#)
3. Hegedüs L, Bonnema SJ, Bennedbæk FN. Management of simple nodular goiter: current status and future perspectives. *Endocr Rev* 2003;24:102-132. [\[Abstract/Full Text\]](#)
4. Bennedbæk FN, Perrild H, Hegedüs L. Diagnosis and treatment of the solitary thyroid nodule: results of a European survey. *Clin Endocrinol (Oxf)* 1999;50:357-363. [\[CrossRef\]](#)[\[ISI\]](#)[\[Medline\]](#)
5. Bennedbæk FN, Hegedüs L. Management of the solitary thyroid nodule: results of a North American survey. *J Clin Endocrinol Metab* 2000;85:2493-2498. [\[Abstract/Full Text\]](#)
6. Jarlov AE, Nygaard B, Hegedüs L, Hart-ling SG, Hansen JM. Observer variation in the clinical and laboratory evaluation of patients with thyroid dysfunction and goiter. *Thyroid* 1998;8:393-398. [\[ISI\]](#)[\[Medline\]](#)
7. Papini E, Guglielmi R, Bianchini A, et al. Risk of malignancy in nonpalpable thyroid nodules: predictive value of ultrasound and color-Doppler features. *J Clin Endocrinol Metab* 2002;87:1941-1946. [\[Abstract/Full Text\]](#)
8. Ito Y, Uruno T, Nakano K, et al. An observation trial without surgical treatment in patients with papillary microcarcinoma of the thyroid. *Thyroid* 2003;13:381-387. [\[CrossRef\]](#)[\[ISI\]](#)[\[Medline\]](#)
9. Hegedüs L. Thyroid ultrasound. *Endocrinol Metab Clin North Am* 2001;30:339-360. [\[ISI\]](#)[\[Medline\]](#)
10. Hamming JF, Goslings BM, van Steenis FJ, van Ravenswaay Claasen H, Hermans J, van de Velde CJ. The value of fine-needle aspiration biopsy in patients with nodular thyroid disease

- divided into groups of suspicion of malignant neoplasms on clinical grounds. Arch Intern Med 1990;150:113-116. [Erratum, Arch Intern Med 1990;150:1088.][[Abstract](#)]
11. Pasiëka JL. Hashimoto's disease and thyroid lymphoma: role of the surgeon. World J Surg 2000;24:966-970.[\[CrossRef\]](#)[\[ISI\]](#)[\[Medline\]](#)
 12. Elisei R, Bottici V, Luchetti F, et al. Impact of routine measurement of serum calcitonin on the diagnosis and the outcome of medullary thyroid cancer: experience in 10,864 patients with nodular thyroid disorders. J Clin Endocrinol Metab 2004;89:163-168.[\[Abstract/Full Text\]](#)
 13. Shambaugh GE III, Quinn JL, Oyasu R, Freinkel N. Disparate thyroid imaging: combined studies with sodium pertechnetate Tc 99m and radioactive iodine. JAMA 1974;228:866-869.[\[CrossRef\]](#)[\[ISI\]](#)[\[Medline\]](#)
 14. Marqusee E, Benson CB, Frates MC, et al. Usefulness of ultrasonography in the management of nodular thyroid disease. Ann Intern Med 2000;133:696-700.[\[Abstract/Full Text\]](#)
 15. Jennings A. Evaluation of substernal goiters using computed tomography and MR imaging. Endocrinol Metab Clin North Am 2001;30:401-414.[\[ISI\]](#)[\[Medline\]](#)
 16. Kang KW, Kim S-K, Kang H-S, et al. Prevalence and risk of cancer of focal thyroid incidentaloma identified by 18F-fluorodeoxyglucose positron emission tomography for metastasis evaluation and cancer screening in healthy subjects. J Clin Endocrinol Metab 2003;88:4100-4104.[\[Abstract/Full Text\]](#)
 17. Mazzaferri EL. Management of a solitary thyroid nodule. N Engl J Med 1993;328:553-559.[\[Full Text\]](#)
 18. Burch HB. Evaluation and management of the solid thyroid nodule. Endocrinol Metab Clin North Am 1995;24:663-710.[\[ISI\]](#)[\[Medline\]](#)
 19. Danese D, Sciacchitano S, Farsetti A, Andreoli M, Pontecorvi A. Diagnostic accuracy of conventional vs. sonography-guided fine-needle aspiration biopsy of thyroid nodules. Thyroid 1998;8:15-21.[\[ISI\]](#)[\[Medline\]](#)
 20. Gharib H, Goellner JR. Fine-needle aspiration biopsy of the thyroid: an appraisal. Ann Intern Med 1993;118:282-289.[\[Abstract/Full Text\]](#)
 21. Hamburger JI. Diagnosis of thyroid nodules by fine needle biopsy: use and abuse. J Clin Endocrinol Metab 1994;79:335-339.[\[Abstract\]](#)
 22. Kuma K, Matsuzuka F, Kobayashi A, et al. Outcome of long standing solitary thyroid nodules. World J Surg 1992;16:583-587.[\[ISI\]](#)[\[Medline\]](#)
 23. Bennedbæk FN, Nielsen LK, Hegedüs L. Effect of percutaneous ethanol injection therapy vs. suppressive doses of L-thyroxine on benign solitary solid cold thyroid nodules: a randomised trial. J Clin Endocrinol Metab 1998;83:30-35.

24. Alexander EK, Hurwitz S, Heering JP, et al. Natural history of benign solid and cystic thyroid nodules. *Ann Intern Med* 2003;138:315-318. [\[Abstract/Full Text\]](#)
25. Hamburger JI. Evolution of toxicity in solitary nontoxic autonomously functioning thyroid nodules. *J Clin Endocrinol Metab* 1980;50:1089-1093. [\[Abstract\]](#)
26. Sandrock D, Olbricht T, Emrich D, Benker G, Reinwein D. Long-term follow-up in patients with autonomous thyroid adenoma. *Acta Endocrinol (Copenh)* 1993;128:51-55. [\[Medline\]](#)
27. Castro MR, Caraballo PJ, Morris JC. Effectiveness of thyroid hormone suppressive therapy in benign solitary thyroid nodules: a meta-analysis. *J Clin Endocrinol Metab* 2002;87:4154-4159. [\[Abstract/Full Text\]](#)
28. Zelmanovitz F, Genro S, Gross JL. Suppressive therapy with levothyroxine for solitary thyroid nodules: a double-blind controlled clinical study and cumulative meta-analyses. *J Clin Endocrinol Metab* 1998;83:3881-3885. [\[Abstract/Full Text\]](#)
29. Papini E, Petrucci L, Guglielmi R, et al. Long-term changes in nodular goiter: a 5-year prospective randomised trial of levothyroxine suppressive therapy for benign cold thyroid nodules. *J Clin Endocrinol Metab* 1998;83:780-783. [\[Abstract/Full Text\]](#)
30. Sawin CT, Geller A, Wolf PA, et al. Low serum thyrotropin concentrations as a risk factor for atrial fibrillation in older persons. *N Engl J Med* 1994;331:1249-1252. [\[Abstract/Full Text\]](#)
31. Surks MI, Ortiz E, Daniels GH, et al. Subclinical thyroid disease: scientific review and guidelines for diagnosis and management. *JAMA* 2004;291:228-238. [\[Abstract/Full Text\]](#)
32. Uzzan B, Campos J, Cucherat M, Nony P, Boissel JP, Perret GY. Effects on bone mass of long term treatment with thyroid hormones: a meta-analysis. *J Clin Endocrinol Metab* 1996;81:4278-4289. [\[Abstract\]](#)
33. McCowen KD, Reed JW, Fariss BL. The role of thyroid therapy in patients with thyroid cysts. *Am J Med* 1980;68:853-855. [\[ISI\]](#)[\[Medline\]](#)
34. Hegedüs L, Nygaard B, Hansen JM. Is routine thyroxine treatment to hinder postoperative recurrence of nontoxic goiter justified? *J Clin Endocrinol Metab* 1999;84:756-760. [\[Abstract/Full Text\]](#)
35. Songun I, Kievit J, Wobbes T, Peerdeman A, van de Velde CJ. Extent of thyroidectomy in nodular thyroid disease. *Eur J Surg* 1999;165:839-842. [\[CrossRef\]](#)[\[ISI\]](#)[\[Medline\]](#)
36. Ferrari C, Reschini E, Paracchi A. Treatment of the autonomous thyroid nodule: a review. *Eur J Endocrinol* 1996;135:383-390. [\[ISI\]](#)[\[Medline\]](#)
37. Nygaard B, Hegedüs L, Nielsen KG, Ulriksen P, Hansen JM. Long-term effect of radioactive iodine on thyroid function and size in patients with solitary autonomously functioning toxic thyroid nodules. *Clin Endocrinol (Oxf)* 1999;50:197-202. [\[CrossRef\]](#)[\[ISI\]](#)[\[Medline\]](#)

38. **Lippi F**, Ferrari C, Manetti L, et al. Treatment of solitary autonomous thyroid nodules by percutaneous ethanol injection: results of an Italian multicenter study. *J Clin Endocrinol Metab* 1996;81:3261-3264.[\[Abstract\]](#)
39. Bennedbæk FN, Karstrup S, Hegedüs L. Percutaneous ethanol injection therapy in the treatment of thyroid and parathyroid diseases. *Eur J Endocrinol* 1997;136:240-250.[\[ISI\]](#)[\[Medline\]](#)
40. Verde G, Papini E, Pacella CM, et al. Ultrasound guided percutaneous ethanol injection in the treatment of cystic thyroid nodules. *Clin Endocrinol (Oxf)* 1994;41:719-724.[\[ISI\]](#)[\[Medline\]](#)
41. Bennedbæk FN, Hegedüs L. Percutaneous ethanol injection therapy in benign solitary solid cold thyroid nodules: a randomised trial comparing one injection with three injections. *Thyroid* 1999;9:225-233.[\[ISI\]](#)[\[Medline\]](#)
42. Zingrillo M, Collura D, Ghiggi MR, Nirchio V, Trischitta V. Treatment of large cold benign thyroid nodules not eligible for surgery with percutaneous ethanol injection. *J Clin Endocrinol Metab* 1998;83:3905-3907.[\[Abstract/Full Text\]](#)
43. Døssing H, Bennedbæk FN, Karstrup S, Hegedüs L. Benign solitary solid cold thyroid nodules: US-guided interstitial laser photocoagulation -- initial experience. *Radiology* 2002;225:53-57.[\[Abstract/Full Text\]](#)
44. Hegedüs L, Hansen JM, Karstrup S, Torp-Pedersen S, Juul N. Tetracycline for sclerosis of thyroid cysts: a randomized study. *Arch Intern Med* 1988;148:1116-1118.[\[Abstract\]](#)
45. Bennedbæk FN, Hegedüs L. Treatment of recurrent thyroid cysts with ethanol: a randomized double-blind controlled trial. *J Clin Endocrinol Metab* 2003;88:5773-5777.[\[Abstract/Full Text\]](#)
46. Feld S, Garcia M, Baskin HJ, et al. AACE clinical practice guidelines for the diagnosis and management of thyroid nodules. *Endocr Pract* 1996;2:78-84.